Check for updates

DOI: 10.1111/jocd.15242

JCD Journal of Cosmetic Dermatology WILEY

1 2 3
4 5 6
7,8 9 10

[1]Department of Dermatology, Venereology & Leprosy, Dr. Rajendra Prasad Government Medical College, Kangra, India

[2]Department of Pharmacology, Dr. DY Patil Medical College, Navi Mumbai, India

[3]Department of Dermatology, Medical University of Warsaw, Warsaw, Poland

[4]Worldwide Laser Institute, Dallas, USA

[5]Boston University School of Medicine, Boston, Massachusetts, USA

[6]Gold Skin Care Center, Tennessee Clinical Research Center, Nashville, Tennessee, USA

[7]Cosmetic Laser Dermatology: A West Dermatology Company, San Diego, California, USA

[8]Department of Dermatology, University of California, San Diego, California, USA

[9]College of Medicine and Health Sciences, United Arab Emirates University, Al Ain, United Arab Emirates

[10]Department of Dermatology, University Medical Center Mainz, Mainz, Germany

Mohamad Goldust, Department of Dermatology, University Medical Center Mainz, Mainz, Germany.
Email: mgoldust@uni-mainz.de

Melasma is a common malady affecting all races with a higher incidence in Hispanics, Middle Eastern, Asians, and African origin females (Fitzpatrick skin phototypes III–V). Women are affected much more often than men. Melasma remains a significant cause of cosmetic morbidity and psychosocial embarrassment affecting quality of life necessitating effective and reliable treatment. Unfortunately, treatment remains unsatisfactory due to limited efficacy, adverse effects, and relapses after stopping treatment. Although chemical peels, laser and light therapies and dermabrasion may have utility, the evidence available for their efficacy is limited and they often cause post-inflammatory hyperpigmentation, particularly in individuals with darker skin types. Medical therapies remain mainstay in the management of melasma. The triple combination, hydroquinone 4%, tretinoin 0.05%, and fluocinolone acetonide 0.01% (Triluma, Galderma, Ft. Worth Texas, often modified incorporating different corticosteroids) remains the only US FDA-approved treatment for melasma and is the gold standard due its demonstrated efficacy across ethnicities. Oral tranexamic acid alone or in combination with other modalities has also shown significant efficacy. Several cosmeceuticals and botanical extracts used as skin lightening agents have been demonstrated to be useful. Physical sunscreens containing zinc oxide, iron oxide, titanium dioxide, and silicones provide photoprotective and camouflage effect. We propose that a multimodality approach to the treatment of melasma is the most effective treatment approach. This review is focused on the medical therapies for melasma.

chemical peels, cosmeceuticals, hydroquinone, natural ingredients, tranexamic acid

Melasma (Greek- Melas; Black) is a common acquired skin hyperpigmentation primarily affecting sun-exposed areas of forehead, cheeks, nose, upper lip, and chin, and occasionally the neck and forearms. Its exact prevalence in general population is understudied but accounts for 5–6 million people in US alone, 0.25%–4% of dermatology clinic attendees in Southeast Asia and it is one of the common pigmentary disorders among Indians.[1] Melasma affects all races but individuals of Hispanic, Latin American, Middle Eastern,

This is an open access article under the terms of the Creative Commons Attribution-NonCommercial License, which permits use, distribution and reproduction in any medium, provided the original work is properly cited and is not used for commercial purposes.
© 2022 The Authors. published by Wiley Periodicals LLC.

Asia and African origin (Fitzpatrick skin phototypes III–V) predominate.[2] Women are affected much more often than men who comprise 10%–20% of cases mostly in their 3rd and 4th decade of life [3–5] Variable presentations are reported based on clinical examination, histology, and intensification of pigment under long wave ultraviolet light (Wood's light) (Table 1). The diagnostic significance of "Fitzpatrick macule," a confetti-like macule of regularly pigmented skin observed in about 89% clinical photographs of large hyperpigmented patch of melasma cases compared with 1% cases of poikiloderma of Civatte and 6% of solar lentigenosis cases has been highlighted recently.[6]

Melasma remains a significant cause of cosmetic morbidity and psychosocial embarrassment affecting quality of life.[3,4] However, treatment remains unsatisfactory for most individuals due to limited efficacy and adverse effects of available therapies, and frequent relapses after stopping treatment. This paper presents an overview of hydroquinone, often used as first-line therapy and non-hydroquinone medical treatment options in patients with melasma.

|

A high incidence of up to 70% in family members favors genetic predisposition to develop melasma. Other frequently implicated etiologic factors include pregnancy, oral contraceptives, endocrine dysfunction, hormone replacement treatments, thyroid disorders, drugs, cosmetic contact sensitivity, light exposure including both sun and artificial light and stress.[7,8] Pigmentation is usually confined to the epidermis, but dermal factors have been implicated for its recurrent and refractory nature. Ultraviolet (UV) irradiation induced increased proliferation on dermal vasculature proliferation and upregulation of dermal proangiogenic factors such as vascular endothelial growth factor (VEGF), basic fibroblast growth factor (bFGF), and interleukin (IL)-8) have been implicated in the pathogenesis of melasma.[9,10] Interaction between VEGF receptors on epidermal keratinocytes and dermal proangiogenic factors leads to release of mediators such as arachidonic acid metabolites and plasminogen from proliferated vessels, which enhance melanogenesis in melasma.[11,12] Plasmin also converts extracellular matrix-bound VEGF into freely diffusible forms and plays an important role in angiogenesis and melanogenesis.

Recently, the role of mast cells in the pathogenesis of melasma has been also highlighted. They are related to various histological changes and their increased number observed in melasma lesions is attributed to repetitive UV irradiation. The mast cell tryptase degrades type IV collagen that might be the cause of weak basement membrane observed in melasma. Solar elastosis is another histological feature of melasma, and elastin content in UV-exposed skin correlates with mast cell counts suggesting their role in this process. Interestingly, in experimental mast cell-deficient mouse models, solar elastosis was not observed even after repeated UV irradiation.[13] The mast cells can also induce vascular proliferation by secreting various dermal proangiogenic factors like VEGF, FGF-2, TGF-B enhancing melanogenesis in melasma.

Recently, the effect of visible light in inducing pigmentation and the role of UV radiation on keratinocyte–melanocyte interaction, dermal inflammation, and fibroblast activation through a complex interaction and interplay between increased melanocyte proliferation, fibroblast activation, stem cell factor, prostaglandin synthesis, inducible nitric oxide synthesis and melanogenesis has been elucidated.[11,12]

for maximum benefit. Newer peels like phytic acid peels and amino fruit acid peel are developed to overcome the drawbacks of conventional peels. Phytic acid peels have low pH and do not need neutralization. They are applied on face overnight and used once every week and clinical effect is observed usually after 5–6 sessions.[17] Recently introduced 10% tretinoin peel mask has shown significant therapeutic benefit in 20 patients with melasma.[32] Ilknur et al.[33] in a single-blinded, randomized study found amino fruit acid peels were superior to glycolic acid peels in melasma treatment after 12 sessions. These carboxylated acidified amino acid peels have an alka-

JCD Journal of Cosmetic Dermatology —WILEY—

Tyrosinase inhibitors	Competitive	Arbutin (α or β Arbutin), Deoxyarbutin, Aleosin, Azelaic acid, Kojic acid, Gentisic acid, Mequinol, Flavonoids
	Non-Competitive	Glabridin, Liqourice extract, Mulberry extract, N-acetyl glucosamine (Chitin), Hydroxystilbenes (resveratrol, genitol),
Melanosome transfer Inhibitors		Niacinamide (Vit B3), Soy extract (Soyabean trypsin inhibitor), Retinoic acid
Melanosome maturation inhibition		Arbutin, Deoxyarbutin
Antioxidants		Vitamin E (α-Tocoferol acetate), Vitamin C (Sodium ascorbyl phosphate, Ascorbyl Palmitate, Ascorbyl Glucoside)
Epidermal turnover enhancers		Retinoic acid, α-hydroxy acids, Salicylic acid, Linoleic acid
Plasmin inhibitor		Tranexamic acid
α-MSH induced melanin reduction		β-carotene
Protease activator receptor-2 inhibitor		Soyabean trypsin inhibitor
By interaction with copper		Kojic acid, Ascorbic acid

Hydroquinone (1,4 dihydroxybenzene), a hydroxyphenolic compound, has been used extensively as a standalone or in combination with other agents for topical treatment of melasma. It inhibits conversion of DOPA to melanin by inhibiting the activity of tyrosinase possibly interacting with copper at the active end of the enzyme.[41] It is also said to alter melanosome formation, increase their degradation, destroy melanocytes, and inhibit DNA and RNA synthesis. It is used topically as a 2% to 5% cream or alcohol-based solution and has been found effective even in monotherapy. The pigmenta-

year.[8,42–45] Hydroquinone 4% has resulted in complete or partial clearance of melasma in 95% patients versus 67% patients in the [46]

Although azelaic acid 20% produced a more favorable response than hydroquinone 2% resulting in excellent or good overall improvement (73.8% vs. 19.4%), hydroquinone 4% was as effective as azelaic acid

the latter.[47–49] It was equally effective as monotherapy in 4% concentration and in a combination with glycolic acid (20%–30%) peel leading to significant improvement in a split face study comprising 21 Hispanic women.[50] Hydroquinone 4% showed a 77% improvement over a 3-month period when compared with a 67% improvement from a skin whitening cream containing extract, fermented , rice extract and grapefruit extract.[51] Pruritus was the major adverse effect from hydroquinone. A twice-daily application of 4% hydroquinone was superior to placebo and improved melasma in 38% and 77% patients versus 10% and 67% patients in placebo group in two separate studies.[46,51] Apparently, a 4% concentration is particularly useful when used as monotherapy. However, nearly 25% patients may experience a dose- and duration-dependent irritation from transient inflammatory reaction with higher concen- [43,44,52]

Mild itching, burning sensation, erythema, irritant and allergic contact dermatitis, transient hypopigmentation, nail discoloration, and post-inflammatory hyperpigmentation are reported more often with 4% than 2% formulations. Prolonged use and higher concentration is also associated with exogenous ochronosis, a difficult-to-treat, gray-blue-black pigmentation over treated areas.[46,51] However, these adverse events may also be associated with other substances added to the hydroquinone formulation.[41,53] Another concern is its propensity for rapid oxidation resulting in unstable formulations, discoloration, decreased efficacy, and actual depigmentation from melanotoxic hydroxybenzoquinone and -benzoquinone, the byproducts of its oxidation.[17] The risk of possible bone marrow toxicity, development of renal adenomas or carcinogenic effect of topical hydroquinone therapy in humans is considered insignificant since it bypasses its metabolism in liver.[41,54] There was also no significant risk for premature death or malignancy among workers exposed to the compound during industrial production than normal population.[41] Nevertheless, its use in over-the-counter cosmetics in USA, Australian, European, Japanese, and Indian markets is not allowed while Poland and West African country Ghana have totally banned it.

Currently, hydroquinone is often used in combination with other agents such as retinoids, topical corticosteroids, kojic acid, and/or glycolic acid for added effect. It is also used along with chemical peels.

The triple combination of hydroquinone with a retinoid and a corticosteroid remains the most studied modality to treat melasma because of improved tolerability and efficacy. The original triple combination developed by Kligman–Willis in 1975 consisted of hydroquinone 5%, tretinoin 0.1%, and dexamethasone 0.1%.[55] Overall, it has been noted that hydroquinone 10% is more effective but highly irritating, tretinoin 0.2% is irritating without being more effective while tretinoin 0.05% is less irritating but takes a long time

14732165, 2022, 9, Downloaded from https://onlinelibrary.wiley.com/doi/10.1111/jocd.15242 by CochraneChina, Wiley Online Library on [12/08/2023]. See the Terms and Conditions (https://onlinelibrary.wiley.com/terms-and-conditions) on Wiley Online Library for rules of use; OA articles are governed by the applicable Creative Commons License

			peels
Very superficial peels		Glycolic acid 30%–50% Trichloroacetic acid (TCA)10% Jessner's solution (1–3 coats) Salicylic acid 20%–30% Lactic acid 50% Tretinoin 1%–5%	Stratum corneum
Superficial peels		Glycolic acid—50%–70% TCA 10%–30% Jessner's solution[a] (4–7 coats)	Epidermis extending to papillary dermis
Medium peels		Glycolic acid 70% TCA 35%–50% Phenol 88% Pyruvic acid	Upper reticular dermis
Deep peels		Baker Gordon phenol formula[b]	Mid reticular dermis
Classic peels	Mono peels	Glycolic acid Trichloroacetic acid Salicylic acid Retinoic acid Phenol	–
	Combination peels	Jessners peel Modified Jessners peel (lactic acid, salicylic acid and citric acid) Baker-Gordon peel (phenol, croton oil, septisol and water) Salicylic - mandelic acid	-
Newer peels	Mono peels	Mandelic acid Pyruvic acid Lactic acid Ferulic acid Jasmonic acid Tartaric acid Malic acid	-
	Combination peels	Salicylic-mandelic acid peel VI peel (TCA 10%–12%, salicylic acid 10%–12%, tretinoin 0.1%–0.4%, phenol 10%–12%, and vitamin C 4% in mineral blend) Phytic acid Lipohydroxy acid Polyhydroxy acid Black peel	-

[a]Jessner's solution: salicylic acid 14%, lactic acid 14%, resorcinol 14% in 95% ethanol.
[b]3 drops of croton oil yielding 48.5% phenol and 2.2% croton oil.

to be effective, and dexamethasone can be increased up to 0.2% to enhance activity without significant difference in irritancy potential.[45,55] Several modifications using different corticosteroids (hydrocortisone 0.1%, mometasone 0.1%, fluticasone 0.1%, betamethasone valerate, flucinolone acetonide 0.01%) have been in use since then. The fluorinated corticosteroids are apparently more effective than non-fluorinated steroids. A formulation of hydroquinone 4%, tretinoin 0.05%, and flucinolone acetonide 0.01% (HTF, Triluma®) remains the only US FDA approved triple combination for melasma therapy. Studies across ethnicities have documented its superior efficacy even in moderate to severe melasma and improved quality of life compared with hydroquinone monotherapy or other combination therapies. This triple combination was more effective

-

tive study in 120 Brazilian patients with moderate-to-severe melasma.[45] A complete clearance of pigmentation in 35% and >75%

49% patients, respectively, in hydroquinone-only group without a significant difference in adverse effects in both the groups. Chan et al.[56] also demonstrated a superior effect of HTF triple combination compared with hydroquinone 4% cream alone in a multicenter randomized study of 206 Southeast Asian patients. Nearly 70% of 125 patients with moderate to severe melasma achieved complete clearance in triple combination group as compared to 44% of 129 patients in hydroquinone group. Similar observations on its efficacy and safety have been made in 1290 Latin American patients

14732165, 2022, 9, Downloaded from https://onlinelibrary.wiley.com/doi/10.1111/jocd.15242 by CochraneChina, Wiley Online Library on [12/08/2023]. See the Terms and Conditions (https://onlinelibrary.wiley.com/terms-and-conditions) on Wiley Online Library for rules of use; OA articles are governed by the applicable Creative Commons License

JCD Journal of Cosmetic Dermatology WILEY

(including 23% Hispanics) in a phase IV community-based study (PIGMENT trial).[57] A statistically significant reduction in degree of melasma was observed and nearly 49% patients improved from moderate or severe (99%) at first visit to absent or mild melasma at

and severe in 6.9% only. Sequential treatment with triple combination cream and IPL was more efficacious than sequential treatment with an inactive (control) cream and IPL in a 10-week split-face study by Goldman et al.[58] They treated 56 patients having moderate to severe melasma with triple combination cream on one side of the face and an inactive control cream on the other side of the face. Patients

treatment one day before IPL treatments. Melasma severity was significantly less with triple combination cream and IPL compared with

The triple combination therapy has also proven impact on improving quality of life in patients with melasma. A statistically significant reduction in MASI and MelasQoL scores observed after 4

Brazilian multicenter study.[59] Similarly, HTF triple combination was superior in improving quality of life in comparative clinical trial for efficacy and safety, and effect on MelasQoL when compared with hydroquinone 4% and tretinoin 0.05% in studies of melasma patients from Latin America, Mexico, and Hispanic women with a range of Fitzpatrick skin types I through VI.[60–62] Triple combination therapy was overall the best topical treatment for melasma in a recent Cochrane review.[63] Its efficacy has been attributed to synergistic effect of individual components and time taken for its beneficial effect with a twice-daily application is roughly three weeks. Tretinoin prevents oxidation of hydroquinone and improves epidermal penetration of other agents while topical corticosteroid decreases cellular metabolism, inhibits melanin synthesis, and reduces irritation from the other two components.[55] Nevertheless, adverse effects such as erythema, burning, pruritus and irritation, dryness and desquamation are not uncommon and other corticosteroid-induced cutaneous adverse effects may occur from its unsupervised prolonged use. Another problem is of post-inflammatory hyperpigmentation from irritant reaction noted in few patients with darker skin. A less frequent application may ameliorate irritation in such patients.

Dual combination treatments tested for melasma include hydroquinone plus retinoic acid or hydroquinone (4%) plus glycolic acid (5–10%) with moderate improvement and generally tolerable irritant effects.[13,64,65] A combination of hydroquinone 4%, glycolic acid 10%, antioxidants and sunscreen showed reduction in melasma pigmen-

seen with antioxidants/sunscreen alone in a comparative study.[66] A combination of hydroquinone and kojic acid or glycolic acid demonstrated a significant decrease in degree of melasma in a study of 39 patients.[67] However, addition of glycolic acid peel did not improve the efficacy of similar regimen of hydroquinone 4% and glycolic acid 10% over 7 months in a Brazilian study.[68]

Mequinol (4-hydroxyanisole, monomethyl ether of hydroquinone), a derivative of hydroquinone with a similar mechanism of action is used as 2% concentration in combination with tretinoin (0.01%) for treating melasma. It was superior in efficacy to hydroquinone 3% and tolerated well in a randomized, parallel-group, double-blind study of 216 patients with solar lentigines/hyperpigmented lesions.[69] Keeling et al.[70] achieved moderate improvement in one and complete clearance with the combination in four males with mel-

tion is usually safe and well tolerated but caused mild erythema, irritation/burning, stinging/tingling, desquamation, pruritus, and hypopigmentation in another open-label study using twice-daily

sions.[71] Experimentally, mequinol was effective in treating melasma and showed less irritant potential than hydroquinone and adverse effects were less than those from monobenzyl ether of hydroquinone.[72,73] Although licensed for monotherapy in Europe and Brazil or in combination with tretinoin in United States and Canada, hydroquinone and not mequinol remains preferred first-line therapy for melasma world over.[74] Few large controlled clinical studies for mequinol in the management of melasma will perhaps resolve issues related to its efficacy and safety for a wider acceptance.

Topical corticosteroids, retinoids, and alpha hydroxy acids (glycolic acid, kojic acid, azelaic acid), several plant extract-based therapies

hypertrichosis, acneiform eruptions, telangiectasias, rosacea, and perioral dermatitis.[16,76] Moreover, the short-lived beneficial effect prompts repeated and prolonged treatment without supervision causing marked skin atrophy and other adverse changes. The mechanism for their skin lightening effect remains poorly understood and is often attributed to their direct anti-metabolic effect on melanin synthesis, alteration of melanocyte function without being melanotoxic and/or inhibition of synthesis of inflammatory mediators such as leukotriene and prostaglandins.[76] Topical use of a potent or super potent corticosteroid alone has demonstrated good therapeutic effect.[77] Corticosteroids such as hydrocortisone, dexamethasone, mometasone furoate, fluocinolone acetonide, and fluticasone remain preferred in (triple) combination therapy of melasma. Once daily futicasone (0.05%) topical application was as effective as betamethasone (0.12%) twice daily or mometasone furoate without hypothalamic-pituitary-adrenal axis suppression and caused less skin atrophy than mometasone furoate and fluocinolone acetonide in the triple combination.[78,79] Topical corticosteroids as monotherapy for melasma are usually not preferred for their atrophogenic potential and other adverse effects, although fluticasone is less atrophogenic than others. However, they are beneficial when used with caution to reduce irritation from other topical agents or when pigmented cosmetic dermatitis is suspected.

|

Tretinoin (0.05%–0.1%) remains a common retinoid used effectively for apparent clinical improvement.[80] It inhibits tyrosinase transcription and related proteins 1 and 2 (TRP-1 and TRP-2) to decrease post-transcriptional levels of tyrosinase and TRP-1and interrupts melanin synthesis after UVB exposure.[13,81–84] Additionally, it also decreases melanosome transfer by accelerating keratinocyte turnover and desquamation.[83] When used in combination, it improves penetration of other active ingredients like hydroquinone and antagonizes atrophogenic effect of corticosteroid.[13] Topical tretinoin lead to 68% improvement in 38 patents over a 40-week treatment period.[85] However, 88% patients experienced burning, itching, erythema, and scaling from continuous therapy. Tretinoin (10%) peeling mask was effective in a study of 20 women with Fitzpatrick skin type II-VI and tretinoin 1% peel was as effective as 70% glycolic acid peel.[32,86] Topical adapalene, isotretinoin and tazarotene are other retinoids used in melasma.[82,83,87] Adapalene is well tolerated and equally effective among retinoids in long-term melasma treatment. Retinol causes less irritation but its comparative efficacy is lower than tretinoin or tazarotene.[41]

|

Kojic acid (5-hydroxy-2-hydrxymethyl-4-pyrne), a metabolite of and certain species of and , inhibits free tyrosinase by chelating copper at the enzyme's active site and exhibits antioxidant effects. It is available in 1–4% concentration and has efficacy almost equal to other therapies. Addition of hydroquinone 2% or glycolic acid (5%–10%) has an augmenting effect. Its combination with hydroquinone 2% was superior in efficacy than kojic acid used alone or its combination with betamethasone valerate 0.1% or glycolic acid 5%, or a combination of betamethasone valerate 0.1% and hydroquinone 2%.[6,88] A combination of kojic acid 2%, glycolic acid 10%, and hydroquinone 2% was more effective in melasma than the same combination without kojic acid in a spilt-face study.[89] The combination of kojic acid 2% and glycolic acid 5% had efficacy equal to that of hydroquinone 2% and glycolic acid 5% in a split-face study to treat melasma.[49] It makes a useful option in patients responding poorly to hydroquinone and glycolic acid or who are intolerant to other first-line therapies. However, it is potentially an irritant and a contact sensitizer and known to cause paradoxical pigmented contact dermatitis.[90]

|

Azelaic acid, a dicarboxylic acid, produced by sp., is responsible for hypopigmentation in tinea versicolor. It has antiproliferative and selective cytotoxic effect on abnormally hyperactive melanocytes by its inhibitory effect on tyrosinase and mitochondrial oxidoreductase enzymes with minimal effects on normally pigmented skin. Azelaic acid (15%–20%) is effective in melasma and post-inflammatory hyperpigmentation as monotherapy and was equally effective as hydroquinone 4% but superior to hydroquinone 2% while its combination with tretinoin 0.05% and glycolic acid 15%–20% showed synergistic effect.[47,48,91,92] A combination of azelaic acid 20% and glycolic acid 15%–20% was as effective as hydroquinone 4% in moderate to severe melasma and other facial hypermelanoses in patients with skin of color.[91] It makes a safe choice in hydroquinone intolerant patients. However, mild and transient itching and burning may occur while acneiform eruptions and telangiectasias, hypertrichosis, vitiligo, and asthma are extremely rare occurrences.[92]

|

Arbutin, a d-glucopyranoside derivative of hydroquinone, derived from bearberry leaves is widely used for its skin lightening and depigmenting effect. It hydrolyses to hydroquinone in vivo and competitively inhibits enzyme tyrosinase and 5,6-dihydroxyindole-2-carboxylic acid polymerase activity in vitro in a dose-dependent manner.[93] Deoxyarbutin and α-arbutin, the synthetic derivatives of arbutin, are more stable and show better efficacy than the natural one. The inhibitory effect of arbutin on tyrosinase activity equals to that of hydroquinone and deoxyarbutin in an in vitro study but is less effective than kojic acid.[41,49]

JCD Journal of Cosmetic Dermatology —WILEY—

less toxic in vitro to melanocytes than hydroquinone. A significant skin lightening and improvement in solar lentigines was observed

with either light or dark skin tones.[93] However, good clinical studies are lacking for its efficacy and safety in patients with melasma.

|

The efficacy of Tranexamic acid (TA) (Trans-4-Aminomethylcyclohe xanecarboxylic acid) in treating melasma has immensely renewed interest for this mode of therapy in recent years. This synthetic derivative of the amino acid lysine is a plasmin inhibitor and antifibrinolytic agent used primarily to prevent and treat blood loss in menstrual disorders and surgeries with high risk of blood loss such as cardiac, liver, vascular, and orthopedic procedures.[94,95] It exerts its effect by reversibly blocking lysine binding sites on plasminogen molecules thus inhibiting plasminogen activator from converting plasminogen to plasmin. It has no effect on coagulation parameters in recommended

-

fore surgery or in 6–8 hourly doses one day prior to surgery. The

-

istration and its absorption is not hampered by food. Approximately 3% of the drug is bound weakly to plasma protein, the plasminogen. Almost 45% of the dose is recovered in the urine in first 3 hours and 90% of the intravenous administered drug is eliminated mostly in one day. The drug can cross the blood–brain barrier and the placenta but excretion into breast milk is minimal.

Sadako[96] incidentally observed that severity of melasma reduced

for urticaria. It has been reported effective when used alone or in combination with other modalities to treat melasma topically (liposome formulations), intradermally (by microinjection), transepidermally (by mesotherapy), orally, or intravenously with comparable efficacy.[15,97–104] Although intravenous TA has been advocated for the "whitening of skin" in Taiwan since 2007, the usual recommended

with normal saline infusion) is potentially risky and considered too low for skin whitening effect.[103] Further, there are no clinical studies to justify such use.

Topical TA 2% or 5% in liposomal formulations has been found effective with clinical effect observed in 2–3 months.[105–107] Although no significant difference was noted between 5% TA versus vehicle in a 12-week randomized controlled split-face study, topical 3% tranexamic acid was as effective as topical hydroquinone 3% and 0.01% dexamethasone combination cream in another similar trial.[105,106] It was also effective as topical emulsion in melasma and

[107]

TA is not commercially available for intralesional use but prepared as

mesotherapy (transepidermally by microneedling or intradermal by localized microinjections) to treat melasma in both genders.[15,102] Lee et al.[99]

from baseline in 100 patients with melasma but injection site erythema and pain were major limiting factors. Although the results were not statistically significant, the improvement in baseline MASI score was better with drug administration by microneedling than microinjections (44.4% vs. 35.7%) in a comparative study comprising two groups of 30 patients each.[98] However, TA by microinjection was superior to topical TA in a small study comparing the two routes of administration.[108] Similarly, an overall efficacy with comparable reduction in MASI score was noted in patients receiving intradermal or oral TA in a recent study.[102] These results suggest that the efficacy of TA is perhaps independent of its route of administration. Nevertheless, direct injection to the affected sites is minimally invasive, offers the advantage of delivering adequate amount of medication directly at the affected skin, and allows use of lower than oral dose. However, pain and discomfort during injection procedure and

by ionotophoresis chemical enhancer and constant electric current may have the advantage of being without pain and discomfort but requires further clinical evaluation.[109]

efficacy (Table 5). Hajime et al.[110] in a study showed 33 of 40 patients

[111]

-

tients with melasma and vitamins C and E only in 30 controls for a pe-

melasma in the treatment group. Similar results were obtained by Liu et al.[112] in a study comprising 176 patients and 70 controls. The treatment group who received oral TA 250mg three times daily, and vita-

showed more improvement with about 24% patients showing 90% improvement and 40% patients having 60% improvement compared with the control group. Thirty-three percent of the 256 melasma patients of Wu et al.[113] showed improvement in the first month from

14732165, 2022, 9, Downloaded from https://onlinelibrary.wiley.com/doi/10.1111/jocd.15242 by CochraneChina, Wiley Online Library on [12/08/2023]. See the Terms and Conditions (https://onlinelibrary.wiley.com/terms-and-conditions) on Wiley Online Library for rules of use; OA articles are governed by the applicable Creative Commons License

			acid					
[15]	66/66	18-52	(Group-A) Topical sunscreen	daily (Group-B) Topical sunscreen		MASI ↓60.1% (Group-A) versus 78.09% (Group-B)	Mild gastrointestinal upset in both groups; oligomenorrhoea in 3 cases in Group-B (self-limiting)	showed early clinical response and overall better efficacy both in per-protocol and intention-to-treat analysis, effective and can be a choice to maintain remission.
[99]	12/0	30–69	+	No control	5 months	11/12 patients had obvious result	Not mentioned	
[102]	130/130	17–55	500 mg/day+ topical hydroquinone and sunscreen	Topical hydroquinone and sunscreen	3 months	mMASI ↓ 82.3% versus 40.8% <	Oligomenorrhea 14.7% Belching 9.2% Abdominal cramp 6.9%	–
[104]	39/41	18–55	250 mg twice daily	Intradermal TXA	3 months	64%>75%↓ 36% 50%–75%↓	Mild gastrointestinal upset in 2 cases; oligomenorrhoea in 6 cases (self-limiting)	Both were equally effective
[106]	24/27	32–50	+	IPL- Nd:Yag		mMASI ↓ 43.8% versus 23.6% <	No significant adverse effect	–
[112]	40/0	24–60	1–1.5 g/day	No control		33/40 patients had decrease severity	Not mentioned	–
[113]	128/30	30–49	+	Vitamin C, E		20% >95% ↓ 30% >60% ↓33% 20–60%↓ <	Gastrointestinal upset in few cases	Observed increase duration of TXA more effective than increased dose. No change in clotting profile
[114]	176/70	25–57	+	Vitamin C, E		24% >90% ↓ 40% >60% ↓ <	5% gastrointestinal upset in both group	No change in clotting profile
[115]	256/0	21–65		No control		10.5% >90% ↓ 18.8% >60% ↓ 51.6% 30%↓	Gastrointestinal upset in 4.3%, oligo- menorrhea in 3.5%	33% response in 1st month, 33% in 2nd month. No change in clotting profile
[116]	99/100	>15		Placebo		76.8% improved versus 27% placebo (<	Transient chest discomfort in one case	–

14732165, 2022, 9, Downloaded from https://onlinelibrary.wiley.com/doi/10.1111/jocd.15242 by CochraneChina, Wiley Online Library on [12/08/2023]. See the Terms and Conditions (https://onlinelibrary.wiley.com/terms-and-conditions) on Wiley Online Library for rules of use; OA articles are governed by the applicable Creative Commons License

[155]	Oral proanthocyanidin (grape seed extract) x 6 months	Efficacy study	Colorimetry Focal macule size	12 women	Maximum improvement occurred after 6 months and none thereafter	Antioxidant properties, reduces melanin biosynthesis, reduces UV-induced hyperpigmentation
[156]	Oral procyanidin with vitamins A, C, E x 8weeks	Efficacy study	–	–	Effective	–
[166]		Open-label, prospective clinical study	Reduction in MASI, Improved MELAS QoL scores, PGA	25 women	MASI decreased and MELAS QoL improved in 74% patients	Inhibition of key enzymes of melanogenesis. Nausea, mild gastrointestinal discomfort.
[151]	Topical -acetyl glucosamine, applied twice daily x 8weeks	Randomized, double-blinded, placebo-controlled split-face clinical trial.	Reduction in MASI score	50 women	improves facial hyperpigmentation	–
[154]	Topical Niacinamide 4% versus hydroquinone 4%	Spilt-face randomized trial	Reduction in MASI score	27 subjects	Both sides responded equally to treatment with progressive reduction in pigmentation	–
[157]	Topical dioic acid 1% versus HQ 2% crème applied twice daily	Open label comparative study	Reduction in MASI score	96 women	Equal therapeutic efficacy	Reduces tyrosinase mRNA expression
[158]	Topical Cysteamine 5% Cream versus placebo cream	Open label comparative study	Reduction in MASI score	25 subjects	Significant reduction in cysteamine treated groups as compared to placebo group	–
[159]	Topical 75% mulberry ( ) extract oil versus placebo versus placebo,	Randomized, single-blind, placebo-controlled trial	Reduction in MASI, Improved MELAS QoL scores	50 subjects	MASI and MELASQoL scores improved significantly in the mulberry group	Tyrosinase inhibition, superoxide scavenging properties. Mild itching.
[160]	Topical Lignin Peroxidase cream	Efficacy study	Reduction in MASI score	31 women	significant reduction in MASI scores	–
[161]	4% cream	Randomized controlled trial	Reduction in MASI score	–	Better reduction in MASI scores from	–
[162]	Topical Flutamide1% cream versus HQ 4% cream	Randomized controlled trial	Reduction in MASI score	74 women	Flutamide showed higher reduction in MASI score versus HQ	–
[163]	Topical methimazole applied for	Case report	Reduction in MASI score	2 HQ resistant cases	Significant improvement noted in both cases	–
[164]	Total soy ( ) extract applied for 3months	Efficacy study	Reduction in hyperpigmentation	16 women	12% reduction in 14 of 16 treated women	–

(Continues)

14732165, 2022, 9, Downloaded from https://onlinelibrary.wiley.com/doi/10.1111/jocd.15242 by CochraneChina, Wiley Online Library on [12/08/2023]. See the Terms and Conditions (https://onlinelibrary.wiley.com/terms-and-conditions) on Wiley Online Library for rules of use; OA articles are governed by the applicable Creative Commons License

JCD Journal of Cosmetic Dermatology —WILEY—

Vitamin E (Alpha-tocopherol), a major lipophilic antioxidant in the tissues, membranes, and plasma, includes four molecules each of tocopherols and tocotrienols occurring naturally. Alpha-tocopherol is the most abundant vitamin E derivative in humans.[142] It has photoprotective effects and cause depigmentation by tyrosinase inhibition, increased intracellular glutathione content and interfering with lipid peroxidation of melanocyte membranes.[143] Alpha-tocopheryl ferulate, a compound of α-tocopherol and ferulic acid, can absorb ultraviolet radiation and reportedly showed significant effect in retardation of melanogenesis.[144] Topical α-tocopherol 5% or less is mostly used in cosmeceuticals in combination with vitamin C for lightening effect. A significant improvement in melasma and pigmented contact dermatitis lesions was observed with topical vitamins E and C in a double-blind study and results were better with combination compared with either vitamin used alone.[145] Allergic or irritant reactions from topical use are infrequent.

Extract of , a tropical fern with anti-inflammatory, antioxidant, and photoprotective properties, has been tried in the oral treatment of melasma with variable results. Nestor et al.[146] in their randomized placebo control study reported significant reduction in MASI scores and melasma quality of life (MelasQoL) scale with oral compared with placebo given twice daily for [147] in a double-blind controlled study reported no significant reduction in MASI score or improvement in MelasQoL scale from its combination with a sunscreen versus sunscreen alone in 40 Hispanic women with moderate to severe melasma randomized to get 240 mg or placebo three timed daily.

Rucinol (4-n-butylresorcinol), a phenolic derivative, inhibits tyrosinase and tyrosinase-related protein (TRP-1). A significant improvement in melasma was seen on treated side in a double-blind of treatment with twice-daily application of rucinol 0.1% cream as compared to vehicle-treated side.[148] Huh et al.[149] in a double-blind split-face randomized controlled trial conducted on 32 women with melasma also reported significant improvement in melasma with ru- compared to vehicle-treated side. The adverse effects of stinging, burning, erythema, dryness, peeling, and desquamation were mild.

Cysteamine, a natural aminothiol biological compound found in mammalian tissues and human milk, provides powerful synergistic effects for skin depigmentation .[171] It is part of the vitamin B3 family and works as antioxidant and inhibits melanosomal transfer. + cream for topical use and has been found very safe with very low risk

Rarely, mild skin irritation (warm sensation, mild redness on immediate application and dryness) may occur temporarily. Its three-product system includes: (1) ® ™ comprises a dual chamber technology that keeps the cysteamine+isobionic-amide complex and alpha hydroxyl acid (AHA) separate until use. The immediate antioxidant effect of isobionic-amide with AHA after application causes instant pigment reduction effect. (2) ® ™ has AHA and L-Arginine - Lactobionic Acid complex to neutralize the odor of cysteamine and re-balance the epidermis before application of Cyspera® Boost™. The L-Arginine complex stops the Isobionic-Amid Complex™ - AHA reaction and the mild-surfactant gently removes any residue, helps soothe skin, and promote healthy skin barrier. The Lactobionic Acid complex neutralizes and balances the skin pH. (3) ® ™ features Isobionic-Amide Complex™ and retinol which works synergistically with Cyspera® Intensive™ to even skin tone, improve complexion and provide natural skin glow. The retinol has an anti-inflammatory effect and leads to a visual pigment reduction by increased skin shedding and non-pigmented skin layers after application of Cyspera® Intensive™.

Although cysteamine formulations have shown significant with placebo and even in a case resistant to Kligman's triple combination therapy, it was not found superior to 4% hydroquinonein or tranexamic acid mesotherapy in comparative trials.[155,172–174] However, a recent systematic review suggests that insufficient sample size, lack of long-term follow-up, and efficacy in cases with epidermal melasma only remain major limitations of clinical studies to draw a meaningful conclusion for the cysteamine's role in treating melasma that often remains unsatisfactorily treated.[175]

It is well established now that both UV radiation and visible light play a significant role in the pathogenesis of melasma. Several studies have demonstrated the benefit of concomitant photoprotection and sunscreens of at least SPF 15 should be prescribed to all patients with melasma (Table 7). The sunscreens effectively reduce pigmentation following sun exposure, significantly increase the efficacy of topical therapy, and prevent relapses of melasma.[176–178] Physical sunscreens containing zinc oxide, iron oxide, titanium dioxide, and silicones (dimethicone, cyclomethicone) are not only photoprotective for the whole spectrum but also provide immediate whitening camouflage effect and are preferred. However, a blend of physical and organic sunscreens can be used for persons who do not find inorganic salts cosmetically elegant because of their high

14732165, 2022, 9, Downloaded from https://onlinelibrary.wiley.com/doi/10.1111/jocd.15242 by CochraneChina, Wiley Online Library on [12/08/2023]. See the Terms and Conditions (https://onlinelibrary.wiley.com/terms-and-conditions) on Wiley Online Library for rules of use; OA articles are governed by the applicable Creative Commons License

JCD Journal of Cosmetic Dermatology

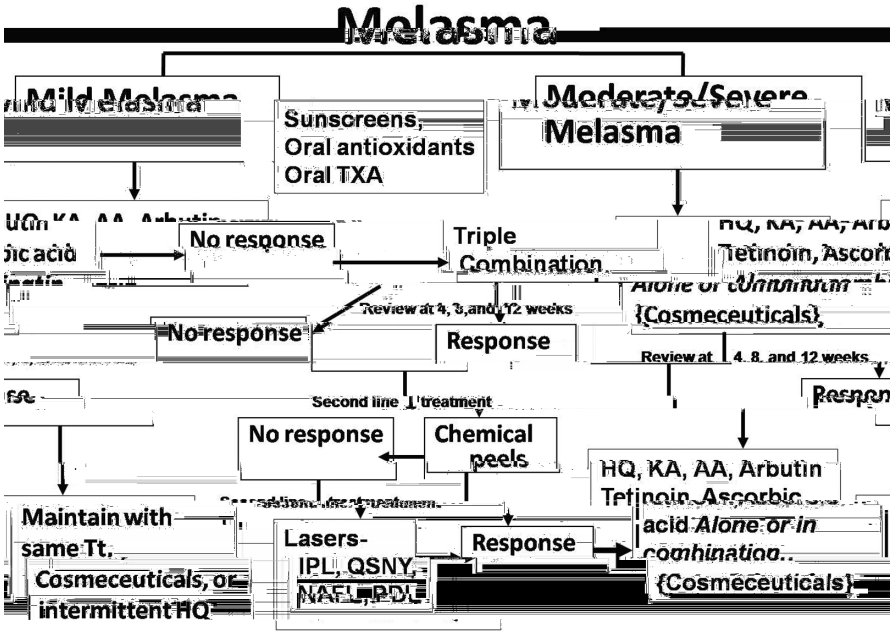

hyperpigmentation, lichen planus pigmentosus, lichen planus actinicus, pigmented cosmetic dermatitis, facial acanthosis nigricans, nevus of Ota, Hori nevus, frictional melanosis, drug-induced pigmentation, photosensitivity disorders, and secondary ochronosis must be excluded. If possible, assessment for melasma should be made both clinically and with Wood's lamp. Advise photoprotection to all patients by physical barriers and prescribe a broad-spectrum sunscreen specially containing titanium oxide/zinc oxide. Consider chemical peels and lasers for resistant cases only. Abbreviations: AA, Azelaic acid; HQ, hydroquinone; IPL, Intense pulse light; KA, Kojic acid; NAFL, Non-ablative fractional laser; PDL, Pulsed dye laser; QSNY, Q-switched Nd:YAG laser; TXA, tranexamic acid.

plasma (PRP) therapy alone or in combination with topical TA or IPL in small studies or that of needling (microneedling, mesoneedling, radiofrequency microneedling) to increase the delivery of topical medications or to induce epidermal thickness for protection against UV radiation remains limited for lack of controlled clinical trials.[179,180]

Pregnancy remains the most common trigger for melasma (mask of pregnancy) and it is mostly treatment-resistant. However, melasma in pregnancy may be transient lasting until parturition and improve significantly thereafter. The treatment during pregnancy is thus usually deferred until delivery/lactation. Nevertheless, physical sunscreen can be prescribed for regular use in the meantime.

Since relapses are common after discontinuation of the treatment, it is imperative to maintain remission and prevent relapse with continuous use of medical therapy that is safe and effective along with adequate sun protection. Relapses are usually treated on sim-

can be used as initial therapy to achieve early clearance of melasma

can be used safely to maintain prolonged remission.[15] Several treatment algorithms have been proposed for mild as well as moderate to severe melasma.[74,181] The suggested treatment algorithm (Figure 2) is simple, easy to follow and can be a quick reference guide in routine office practice. Nevertheless, a multimodality approach such as using a topical formulation, sunscreen, oral TA, and

in combination or in a sequential manner with IPL and/or PDL to treat the vascular component then a low fluence 1927 nm laser will perhaps provide an effective treatment approach.

Vikram K Mahajan involved in conception, writing and revising the manuscript. Anant Patil, Martin Kassir, Nellie Konnikov, Michael H. Gold, Mitchel P Goldman, Hassan Galadari, and Leszek Blicharz involved in review and revising the manuscript. Mohamad Goldust involved in conception, writing, review, and revising the manuscript. We confirm that the manuscript has been read and approved by all the authors, that the requirements for authorship as stated earlier in this document have been met and that each author believes that the manuscript represents honest work.

Open Access funding enabled and organized by Projekt DEAL.

None.

No ethical approval was required as this research did not involve human subjects or animals.

The data that support the findings of this study are available from the corresponding author upon reasonable request.

14732165, 2022, 9, Downloaded from https://onlinelibrary.wiley.com/doi/10.1111/jocd.15242 by CochraneChina, Wiley Online Library on [12/08/2023]. See the Terms and Conditions (https://onlinelibrary.wiley.com/terms-and-conditions) on Wiley Online Library for rules of use; OA articles are governed by the applicable Creative Commons License

https://orcid.org/0000-0002-0537-4066
https://orcid.org/0000-0002-9455-4025
https://orcid.org/0000-0002-5183-5433
https://orcid.org/0000-0001-8223-2769
https://orcid.org/0000-0002-8646-1179

1. Pasricha JS, Khaitan BK, Dash S. Pigmentary disorders in India. . 2007;25:343-352.
2. Achar A, Rathi SK. Melasma: a clinico-epidemiological study of 312 cases. . 2011;56:380-382.
3. Picardo R, Vallejos Q, Feldman SR, et al. The prevalence of melasma and its association with quality of life among male migrant Latino workers. . 2009;48:22-26.
4. Kagha K, Fabi S, Goldman MP. Melasma's impact on quality of life. . 2020;19:184-187.
5. Sarkar R, Puri P, Jain RK, Singh A, Desai A. Melasma in men: a clinical, aetiological and histological study. . 2010;24:68-72.
6. Wu R, Fitzpatrick RE, Goldman MP. Confetti-like sparing: a diagnostic clinical feature of melasma. . 2016;9:48-57.
7. Guinot C, Cheffai S, Latreille J, et al. Aggravating factors for melasma: a prospective study in 197 Tunisian patients. . 2010;24:1060-1069.
8. Prabha N, Mahajan VK, Mehta KS, et al. Cosmetic contact sensitivity in patients with melasma: results of a pilot study. . 2014;2014:316219. doi:10.1155/2014/316219
9. Maeda K, Naganuma M. Topical trans-4-aminomethylcyclohexanecarboxylic acid prevents ultraviolet radiation-induced pigmentation. . 1998;47:136-141.
10. Maeda K, Tomitab Y. Mechanism of the inhibitory effect of tranexamic acid on melanogenesis in cultured human melanocytes in the presence of keratinocyte-conditioned medium. . 2007;53:389-396.
11. Kim EH, Kim YC, Lee ES, Kang HY. The vascular characteristics of melasma. . 2007;46:111-116.
12. Noh TK, Choi SJ, Chung BY, et al. Inflammatory features of melasma lesions in Asian skin. . 2014;41:788-794.
13. Rendon M. Utilizing combination therapy to optimize melasma outcomes. . 2004;3:527-534.
14. Pandya AG, Hynan LS, Bhore R, et al. Reliability assessment and validity of the Melasma Area and Severity Index (MASI) and a new MASI scoring method. . 2011;78:78-83.
15. Chowdhary B, Mahajan VK, Mehta KS, et al. Therapeutic efficacy and safety of oral tranexamic acid 250 mg once a day versus 500 mg twice a day: a comparative study. . 2021;313:109-117.
16. Menter A. Rationale for the use of topical corticosteroids in melasma. . 2004;3:169-174.
17. Sarkar R, Bansal S, Garg VK. Chemical peels for melasma in dark-skinned patients. . 2012;5:247-253.
18. Khunger N, Chanana C. A perspective on what's new in chemical peels. . 2022;2:14.
19. Arora P, Sarkar R, Garg VK, Arya L. Lasers for treatment of melasma and post-inflammatory hyperpigmentation. . 2012;5:93-103.
20. Fabi SG, Friedmann DP, Massaki ABN, Goldman MP. A randomized split-face clinical trial of low-fluence Q switched neodymium-doped yttrium aluminum garnet (1,64-nm) laser versus low-fluence Q-switched alexandrite laser (755-nm) for the treatment of facial melasma. . 2014;46:531-537.
21. Vachiramo V, Sirithanabadeekul P, Sahawatwong S. Low-fluence Q-switched Nd:YAG 1064-nm laser and intense pulsed light for the treatment of melasma. . 2015;29:1339-1346.
22. Moubasher AE, Youssef EM, Abou-Taleb DA. Q-switched Nd:YAG laser versus trichloroacetic acid peeling in the treatment of melasma among Egyptian patients. . 2014;40:874-882.
23. Yun WJ, Mon HR, Lee MW, Choi JH, Chang SE. Combination treatment of low-fluence 1064-nm Q-switched Nd-YAG laser with noel intense pulse light in Korean melasma patients: a prospective, randomized, controlled trial. . 2014;40:842-850.
24. Attawa E, Khater M, Assaf M, Heleem MA. Melasma treatment using an erbium:YAG laser: a clinical, imunohistochemical, and ultrastructural study. . 2015;54:235-244.
25. Wanitphakdeedecha R, Keoprasom N, Empunth S, Manuskiatti W. The efficacy in melasma treatment using a 1410-nm fractional photothermolysis laser. . 2014;2:293-297.
26. Massak AN, Eimpunth S, Fabi SG, et al. Treatment of melasma with the 927-nm fractional thulium fiber laser: a retrospective analysis of 20 cases with long-term follow -up. . 2013;45:95-101.
27. Kroon MW, Wind BS, Beek JF, et al. Non-ablative 1550-nm fractional laser therapy versus triple topical therapy for the treatment of melasma: a randomized controlled pilot study. . 2011;64:516-523.

the use of intense pulsed light: a review. . 2012;11:1316-1320.
29. Hilton S, Heise H, Buhren BA, et al. Treatment of melasma in Caucasian patients using a novel 94-m Q-switched ruby fractional laser. . 2013;18:43.
30. Garg S, Tuknayat A, Hans T. How I manage resistant melasma? . 2022;2:8.
31. Shankar K, Godse K, Aurangabadkar S, et al. Evidence-based treatment for melasma: expert opinion and a review. . 2014;4:165-186.
32. Ghersetich I, Troiano M, Brazzni B, Arunachalam M, Loti T. Melasma: treatment with 10% tretinoin peeling mask. . 2010;9:117-121.
33. Ilknur T, Bicak MU, Demirtasoglu M, Ozkan S. Gycolic acid peels versus amino fruit acid peels in the treatment of melasma. . 2010;36:490-495.
34. Stoner J, Jegasothy M. Acidified amino acid in the management of melasma. . 2008;21:139-140.
35. Rendon MI, Berson DS, Cohen JL, et al. Evidence and considerations in the application of chemical peels in skin disorders and aesthetic resurfacing. . 2010;3:32-43.
36. Wang CC, Hui CY, Sue YM, et al. Intense pulsed light for treatment of refractory melasma in Asian persons. . 2004;30:1196-1200.
37. Manalato RMP, Alster T. Erbium:YAG laser resurfacing for refractory melasma. . 1999;25:121-123.
38. Angsuwarangsee S, Polnikorn N. Combined ultrapulse CO_2 laser and Q-switched alexandrite laser compared with Q-switched alexandrite alone for refractory melasma: split-face design. . 2003;29:59-74.
39. Taylor CR, Anderson RR. Ineffective treatment of refractory melasma and hyperpigmentation by Q-switched ruby laser. . 1994;20:592-597.
40. McKesey J, Tovar-Garza A, Pandya AG. Melasma treatment: an evidence based review. . 2020;21:173-225.

-
troversy. . 2007;20:308-313.

14732165, 2022, 9, Downloaded from https://onlinelibrary.wiley.com/doi/10.1111/jocd.15242 by CochraneChina, Wiley Online Library on [12/08/2023]. See the Terms and Conditions (https://onlinelibrary.wiley.com/terms-and-conditions) on Wiley Online Library for rules of use; OA articles are governed by the applicable Creative Commons License

42. Grimes PE. A microsponge formulation of hydroquinone 4% and retinol 0.15% in the treatment of melasma and post inflammatory hyperpigmentation. . 2004;74:362-368.
43. Bandyopadhyay D. Topical treatment of melasma. . 2009;54:303-309.
44. Guevara IL, Pandya AG. Melasma treated with hydroquinone, tretinoin and a fluorinated steroid. . 2001;40:212-215.
45. Cestari TF, Hassan K, Sittart A, de Lourdes VM. A comparison of triple combination cream and hydroquinone 4% cream for the treatment of moderate to severe facial melasma. . 2007;6:36-39.
46. Ennes SBP, Paschoalick RC, Mora M. A double-blind trial, comparative, placebo-controlled study of the efficacy and tolerability of 4% hydroquinone as a depigmenting agent in melasma. . 2000;11:173-179.
47. Verallo-Rowell VM, Verallo V, Graupe K, et al. Double-blind comparison of azelaic acid and hydroquinone in the treatment of melasma. . 1989;143:58-61.
48. Balina LM, Graupe K. The treatment of melasma. 20% azelaic acid versus 4% hydroquinone cream. . 1991;30:893-895.
49. Lim J. Treatment of melasma using kojic acid in a gel containing hydroquinone and glycolic acid. . 1999;25:282-284.
50. Hurley ME, Guevara IL, Gonzales RM, Pandya AG. Efficacy of glycolic acid peels in the treatment of melasma. . 2002;138:1578-1582.
51. Haddad AL. A clinical, prospective, randomized, double-blind trial comparing skin whitening complex with hydroquinone vs. placebo in the treatment of melasma. . 2003;42:153-156.
52. Sarkar R, Chug S, Garg VK. Newer and upcoming therapies in the treatment of melasma. . 2012;48:417-428.
53. Khunger N, Kandhari R. Dermaoscopic criteria for differentiating exogenous ochronois from melasma. . 2013;9:819-821.
54. Nordlund JJ, Grimes PE, Ortonne JP. The safety of hydroquinone. . 2006;20:308-313.
55. Kligman AM, Willis I. A new formula for depigmenting human skin. . 1975;111:40-48.
56. Chan R, Park KC, Lee MH, et al. A randomized controlled trial of the efficacy and safety of a fixed combination (fluocinolone acetonide 0.01%, hydroquinone 4%, tretinoin 0.05%) compared with hydroquinne 4% cream in Asian patients with moderate to severe melasma. . 2008;159:697-703.
57. Grimes PE, Kell PE, Willis I. Community based trial of triple-combination agent for the treatment of melasma. . 2006;77:177-184.
58. Goldman MP, Gold MH, Palm MD, et al. Sequential treatment with triple combination cream and intense pulsed light is more efficacious than sequential treatment with an inactive (control) cream and intense pulsed light in patients with moderate to severe melasma. . 2011;37:224-233.
59. Cestari TF, Hexsel D, Viegas ML, et al. Validation of a melasma quality of life questionnaire for Brazilian Portuguese language: the MelasQoL-BP study and improvement of QoL of melasma patients after triple combination therapy. . 2007;156(Suppl 1):13-20.
60. Balkrishnan R, Kelly AP, McMichael A, Torok H. Improved quality of life with effective treatment of facial melasma: the PIGMENT trial. . 2004;3:377-381.
61. Arellano I, Leon G, Luna C, et al. Quality of life in Mexican patients with melasma. . 2006;19:343-345.
62. Pawaskar MD, Parikh P, Markowski T, et al. Melasma and its impact on health-related quality of life in Hispanic women. . 2007;18:5-9.
63. Jutley GS, Rajaratnam R, Halpern J, Salim A, Emmett C. Systematic review of randomized controlled trials on interventions for melasma: an abridged Cochrane review. . 2014;70:369-373.
64. Picardo M, Carrera M. New and experimental treatments of cloasma and other hypermelanoses. . 2007;25:353-362.
65. Yoshimura K, Kiyonori H, Aoyama T, Iga T. Experience with a strong bleaching treatment for skin hyperpigmentation in Orientals. . 2000;105:1097-1108.
66. Guevara IL, Pandya AG. Safety and efficacy of 4% hydroquinone combined with 10% glycolic acid, antioxidants, and sunscreen in the treatment of melasma. . 2003;42:966-972.
67. Garcia A, Fulton JE Jr. The combination of glycolic acid and hydroquinone or kojic acid for the treatment of melasma and related conditions. . 1996;22:443-447.
68. Macedo FS, Kaminsky KK, Bagatin E, et al. Melasma: a comparative study of the combination of glycolic acid and hydroquinone in association with glycolic acid peelings. . 2006;34:11-16.
69. Jarratt M. Mequinol 2%/tretinoin 0.01% solution: an effective and safe alternative to hydroquinone 3% in the treatment of solar lentigines. . 2004;74:319-322.
70. Keeling J, Cardona L, Benitez A, Epstein R, Rendon M. Mequinol 2% tretinoin 0.01% topical solution for the treatment of melasma in men: a case series and review of the literature. . 2008;81:179-183.
71. Colby SI, Schwartzel EH, Huber FJ, et al. A promising new treatment for solar lentigines. . 2003;2:147-152.
72. Nair X, Tramposch KM. The Yucatan miniature swine as an in vivo model for screening skin depigmentation. . 1991;2:428-433.
73. Azulay-Abulafia L, Tanaka R, Spinelli L, et al. Topical treatment of melasma with monomethyl ether of hydroquinone (MMEH). Efficacy clinic study. . 2003;60:595-600.
74. Cestari T, Arellano I, Hexsel D, Ortonne JP. Melasma in Latin America: options for therapy and treatment algorithm. . 2009;23:760-772.
75. Sarkar R, Chug S, Garg VK. Newer and upcoming therapies for melasma. . 2012;78:417-428.
76. Gupta AK, Gover MD, Nouri K, Taylor S. The treatment of melasma: a review of clinical trials. . 2006;55:1048-1065.
77. Kanwar AJ, Dhar S, Kaur S. Treatment of melasma with potent topical corticosteroids. . 1994;188:170.

. 2012;57:324-326.
79. Jamkhedkar P, Shenai C, Shroff HJ, et al. Fluticasone propionate (0.05%) cream compared to betamethasone valerate (0.12%) cream in the treatment of steroid-responsive dermatoses: a multicentric study. . 1996;62:289-294.
80. Sheth VM, Pandya AG. Melasma: a comprehensive update: part II. . 2011;65:699-715.
81. Shankar K, Godse K, Aurangabadkar S, et al. Evidence based treatment for melasma: expert opinion and a review. . 2014;5:165-186.
82. Ortonne P. Retinoid therapy of pigmentary disorders. . 2006;19:280-288.
83. Leenutaphong V, Nettakul A, Rattanasuwon P. Topical isotretinoin for melasma in Thai patients: a vehicle controlled clinical trial. . 1999;82:868-875.
84. Roméro C, Aberdam E, Larnier C, Ortonne JP. Retinoic acid as modulator of UVB-induced melanocyte differentiation. Involvement of the melanogenic enzyme expression. . 1994;107:1095-1103.
85. Griffiths CE, Finkel LJ, Ditre CM, et al. Topical tretinoin (retinoic acid) improves melasma. A vehicle controlled clinical trial. . 1993;129:415-421.
86. Faghihi G, Shahingohar A, Siadat AH. Comparison between 1% tretinoin peeling versus 70% glycolic acid peeling in the

14732165, 2022, 9, Downloaded from https://onlinelibrary.wiley.com/doi/10.1111/jocd.15242 by CochraneChina, Wiley Online Library on [12/08/2023]. See the Terms and Conditions (https://onlinelibrary.wiley.com/terms-and-conditions) on Wiley Online Library for rules of use; OA articles are governed by the applicable Creative Commons License

132. Arjinpathana N, Asawanonda P. Glutathione as an oral whitening agent: a randomized, double-blind, placebo-controlled study. . 2012;23:97-102.
133. Rendon MI, Gaviria JI. Review of skin- lightening agents. . 2005;31:886-888.
134. Taylor MB, Yanaki JS, Draper DO, Shurtz JC, Coglianese M. Successful short-term and long-term treatment of melasma and post inflammatory hyperpigmentation using vitamin C with a full face iontophoresis mask and a mandelic/malic acid skin care regimen. . 2013;12:45-50.
135. Espinal-Perez LE, Moncada B, Castanedo-Cazares JP. A double blind randomised trial of 5% ascorbic acid vs. 4% hydroquione in melasma. . 2004;43:604-607.
136. Hwang SW, Oh DJ, Lee D, Kim JW, Park SW. Clinical efficacy of 25% L-ascorbic acid (C'ensil) in the treatment of melasma. . 2009;13:74-81.
137. Huh CH, Seo KI, Park YJ, Lim JG, Eun HC, Park KC. A randomized, double-blind, placebo-controlled trial of vitamin C iontophoresis in melasma. . 2003;206:316-320.
138. Balevi A, Ustuner P, Özdemir M. Salicylic acid peeling combined with vitamin C mesotherapy versus salicylic acid peeling alone in the treatment of mixed type melasma: a comparative study. . 2017;19:294-299.
139. Lee GSK. Intravenous vitamin C in the treatment of post-laser hyperpigmentation for melasma: a short report. . 2008;10:234-236.
140. Lee MC, Chang SC, Huang YL, et al. Treatment of melasma with mixed parameters of 1,064-nm Q-switched Nd: YAG laser toning and an enhanced effect of ultrasonic application of vitamin C: a split-face study. . 2015;301:159-163.

ruby laser (QSRL) combined with sonophoresis on levorotatory vitamin C for treatment of melasma in Chinese patients. . 2016;315:991-995.
142. Thiele JJ, Hsieh SN, Ekanayake-Mudiyanselage S. Vitamin E: critical review of its current use in cosmetic and clinical dermatology. . 2005;31:805-813.

-
meceuticals for women of color. . 2007;6:32-39.
144. Funasaka Y, Komoto M, Ichihashi M. Depigmenting effect of alpha-tocopheryl ferulate on normal human melanogenesis. . 2000;13:170-174.
145. Hayakawa R, Ueda H, Nozaki T, et al. Effects of combination treatment with vitamins E and C on chloasma and pigmented contact dermatitis. A double blind controlled clinical trial. . 1981;3:31-38.
146. Nestor M, Bucay V, Callender V, Cohen J, Sadick N, Wadorf H. as an adjunct treatment of pigmentary disorders. . 2004;7:13-

post-inflammatory hyperpigmentation, and lentigines. . 2021;20:1276-1279.

172. Kasraee B, Mansouri P, Farshi S. Significant therapeutic response to cysteamine cream in a melasma patient resistant to Kligman's formula. . 2019;18:293-295.
173. Lima PB, Dias JAF, Cassiano D, et al. A comparative study of topical 5% cysteamine versus 4% hydroquinone in the treatment of facial melasma in women. . 2020;59:1531-1536.
174. Karrabi M, Mansournia MA, Sharestanaki E, Abdollahnejad Y,